

Case Report

A Noncompliant, High Pressure Balloon to Manage Undilatable Coronary Lesions

Yogesh Raja, MD, MRCP, Helen C. Routledge, BSc, MD, MRCP,
and Sagar N. Doshi,* MBChB, BSc, MD, FRCP

Undilatable coronary lesions, due to coronary calcification, are encountered with increasing frequency. Percutaneous intervention of such lesions comes with the risk of stent underexpansion, which increases the risk of stent thrombosis and restenosis. A variety of techniques and devices are available to assist the interventionist in the treatment of calcified lesions. The OPN NC (SIS-Medical AG, Winterthur, Switzerland) is a high-pressure balloon (rated burst pressure 35 atm) that uses a novel, twin-layer balloon technology to ensure uniform balloon expansion, eliminating "dog-boning." We report four cases of successful treatment of calcified lesions with the OPN NC balloon after dilatation with standard noncompliant balloons to high-pressure failed. © 2010 Wiley-Liss, Inc.

Key words: Undilatable lesions; coronary calcification; OPN NC balloon; coronary angioplasty

INTRODUCTION

As a consequence of an ageing population and an increased prevalence of hypertension, diabetes, and renal failure, all known to be risk factors for coronary calcification [1], undilatable coronary lesions pose a growing problem for the interventional cardiologist. Calcified vessels frequently dissect during lesion preparation. In addition, the inability to fully dilate a lesion may lead to stent underexpansion, so increasing the risk of restenosis and the dreaded complication of stent thrombosis. A variety of strategies and technologies have been developed to combat the problem posed by calcified lesions. These include simple dilatation using standard noncompliant balloons, plaque modification using rotational atherectomy [2] and devices/strategies using "focused-force" angioplasty such as multiple buddy wires [3], Cutting Balloons [4], and the AngioSculpt [5] scoring balloon.

Some of these devices, however, require specific training, expertise and experience and their increased complexity inevitably results in a higher rate of complications. Rotational atherectomy, for example, was associated with a 0.7% risk of vessel perforation in a US multicentre experience [6], as compared with a 0.1% risk in standard procedures. Device entrapment has been reported with the AngioSculpt [7] and Cutting

Balloon [8] and the latter device can also cause perforation [9].

A recent addition to the options available for treatment of resistant lesions is the OPN NC, a super high-pressure, highly noncompliant and readily deliverable balloon catheter. The balloon benefits from a twin-layer technology (patent filed) which ensures uniform expansion, virtually eliminating "dog-boning." We report four cases in which use of the OPN NC balloon resulted in successful treatment of heavily calcified/noncompliant lesions, resistant to high pressure

Department of Interventional Cardiology, Queen Elizabeth University Hospital, Birmingham, United Kingdom

Conflict of interest: Nothing to report.

*Correspondence to: Sagar N. Doshi, MBChB, BSc, MD, FRCP, Cardiology Department, Queen Elizabeth University Hospital, Edgbaston, Birmingham B15 2TH, United Kingdom.
E-mail: sagar.doshi@uhb.nhs.uk

Received 6 December 2009; Revision accepted 21 December 2009

DOI 10.1002/ccd.22430

Published online 00 Month 2009 in Wiley InterScience (www.interscience.wiley.com)

dilatation with standard noncompliant balloons. To our knowledge, this is the first published report describing the utility of this device.

Case 1

A 77-year-old male with type-2 diabetes mellitus, hypertension, hypercholesterolaemia, and renal impairment presented with chest pain and dyspnoea. His EKG showed marked anterior ST-depression and cardiac biomarkers were elevated. Coronary angiography revealed a severe, calcified lesion in the mid left anterior descending (LAD) artery (Fig. 1a).

Via right femoral access, a 6F contralateral support guiding catheter was used to engage the left main stem, and a 0.014" wire was passed to the distal LAD. In view of calcification, visible on fluoroscopy, a non-compliant balloon was chosen to dilate the lesion. Moderate resistance was encountered in passage of a 2.5 mm × 12 mm Sprinter NC balloon (Medtronic, Minneapolis, USA) which was inflated to 16 and subsequently 30 atm. Significant "dog-boning" of the balloon was evident on the angiogram indicative of a highly resistant lesion (Fig. 1b). Repeat angiography showed little change in the lesion but the presence of a non flow-limiting, localized dissection. Because of this

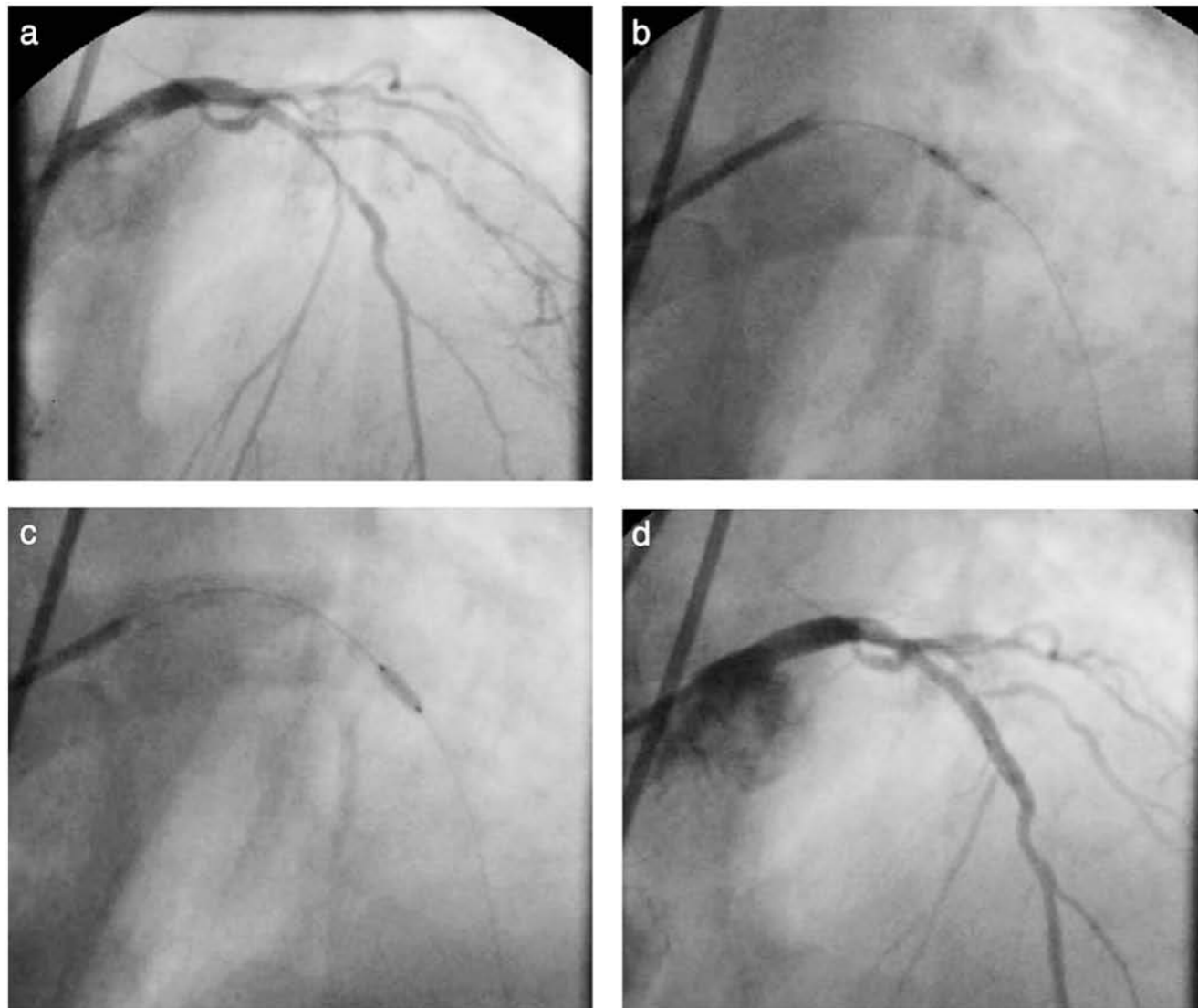


Fig. 1. (a) Diagnostic angiogram (AP projection) of the left coronary artery showing a severe stenosis of the mid LAD. (b) Severe "dog-boning" of a 2.5 mm × 12 mm Sprinter NC balloon observed at 30 atm. (c) The resistant lesion was successfully dilated with a 2.5 mm × 10 mm OPN NC balloon at 35 atm. (d) Final angiogram showed full, uniform expansion of the 2.75 mm × 18 mm Cypher Select stent with absence of perforation and dissection.

appearance and in view of the difficulties in balloon delivery, use of a Cutting Balloon was felt to be hazardous. Rotational atherectomy, already relatively contra-indicated in the presence of dissection, was also rejected in this emergency "out of hours" case, in the absence of appropriately experienced technicians.

Instead, a 2.5 mm × 10 mm OPN NC balloon was selected and delivered to the lesion with ease. This was inflated to 35 atm and full, uniform expansion was observed on the angiogram (Fig. 1c). Subsequent images showed no extension of the dissection and no perforation. A 2.75 mm × 18 mm Cypher Select stent was successfully deployed with full expansion at 18

atm. The final angiogram showed a uniform stent-lumen (Fig. 1d). On image review, quantitative coronary angiography measured the maximum diameter of the 2.5 mm Sprinter NC (at 30 atm) at 2.62 mm, whereas the maximum diameter of the 2.5 mm OPN NC (at 35 atm) reached only 2.1 mm.

Case 2

A 75-year-old female smoker was admitted electively for angioplasty to a severely diseased right coronary artery (Fig. 2a). Via the right radial artery, a 6F AL1 guiding catheter was used to engage the right

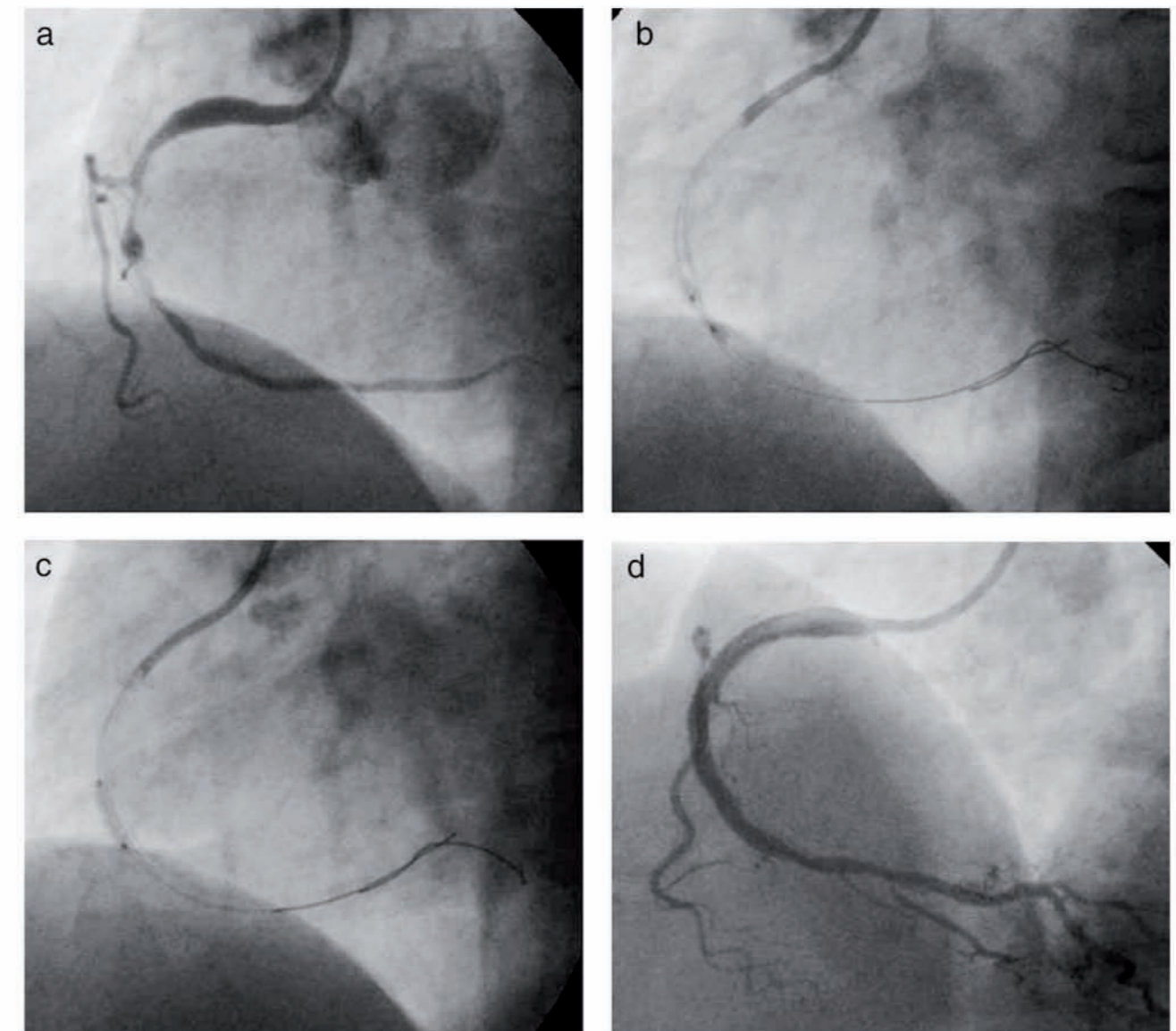


Fig. 2. (a) Diagnostic angiogram (LAO projection) showing severe tandem lesions in the mid RCA. (b) Severe "dog-boning" of a 2.5 mm × 6 mm Sprinter NC at 22 atm was observed at area of focal resistance. (c) The resistant lesion yielded with a 2.5 mm × 10 mm OPN NC at 30 atm. (d) Final angiogram showed full stent expansion at the lesion.

coronary artery. A standard 0.014" wire was advanced to the distal vessel together with a more supportive "buddy-wire." After significant "dog-boning" was observed with a 2.5 mm × 15 mm NC Sprinter at 18 atm, further dilatation was attempted with a 2.5 mm × 6 mm NC Sprinter to 22 atm (Fig. 2b). With little change in the appearance of this lesion, a 2.5 mm × 10 mm OPN NC was used to dilate the lesion and full expansion was observed at 30 atm (Fig. 2c). Subsequent delivery and deployment of stents was uncomplicated and the final angiogram showed uni-

form stent deployment at the site of the resistant lesion (Fig. 2d).

Case 3

A 68-year-old male with a history of cigarette smoking and hypertension was admitted electively for rotational atherectomy of a calcified lesion in the proximal LAD. A prior attempt at angioplasty 3 weeks earlier was unsuccessful with failure to dilate the lesion using a 2.5 mm × 15 mm NC Sprinter at 20 atm (Fig. 3a).

F3

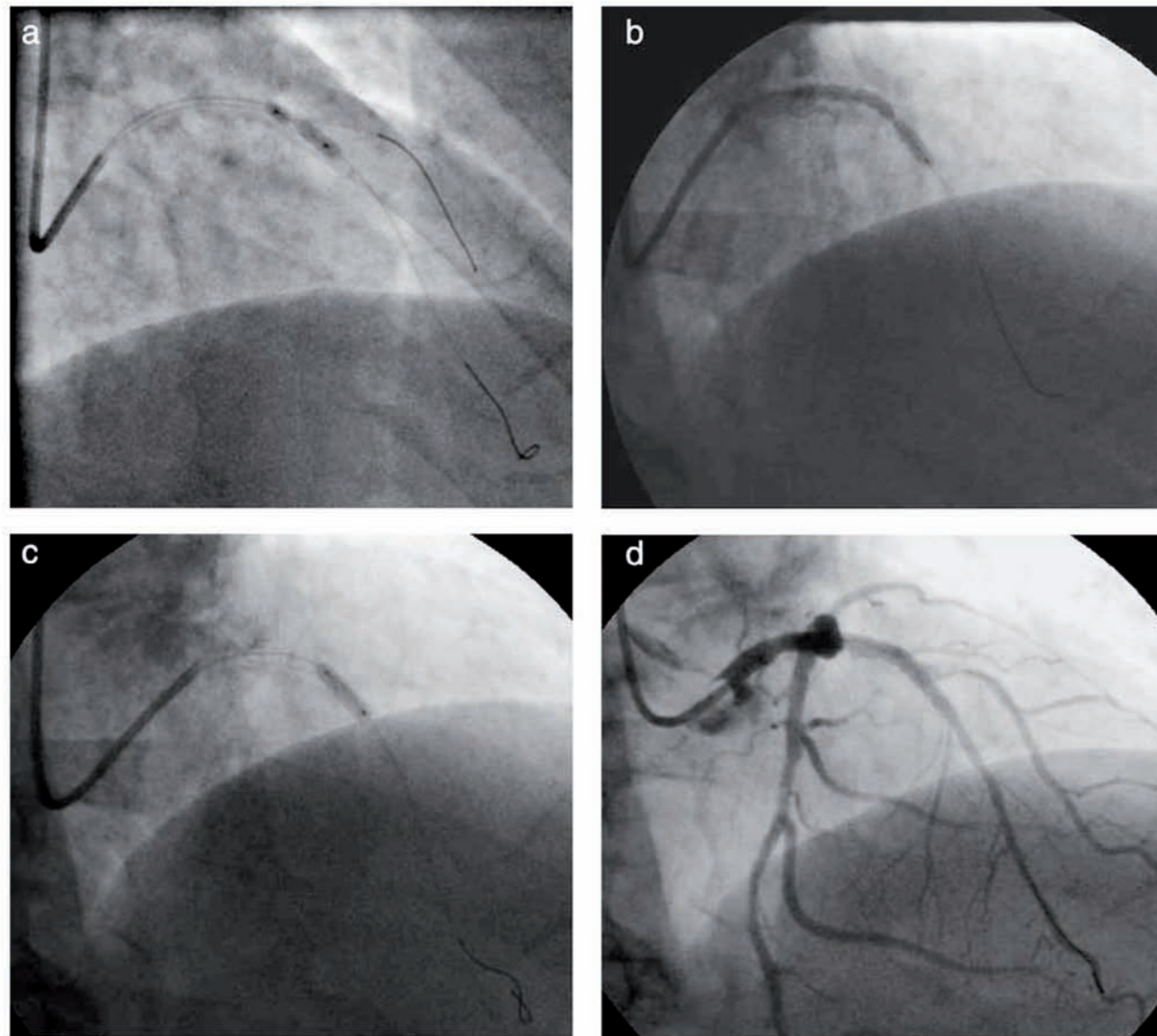


Fig. 3. (a) Focal underdeployment of a 2.5 × 15 mm Sprinter NC was observed at 20 atm at a resistant lesion in the proximal LAD. (b) The lesion was treated with rotational atherectomy (1.5 and 1.75 mm burrs), but severe, focal underexpansion was noted of a 2.75 mm × 28 mm Cypher Select stent deployed at 20 atm. (c) The area of stent underexpansion was successfully treated with a 3 mm × 10 mm OPN NC at 28 atm after failed dilatation with a 3 mm × 15 mm Sprinter NC at 20 atm. (d) Final angiogram showed full and uniform stent expansion.

A 6F contralateral support guide catheter was used to engage the left main stem via right radial artery access. Rotational atherectomy was performed with a 1.5 and subsequently a 1.75 mm burr. The lesion was then predilated with a 2.5 mm × 15 mm NC Sprinter to 16 atm, with apparent full balloon expansion although in retrospect a discrete area of underdeployment persisted. A 2.75 mm × 28 mm Cypher Select was deployed at 20 atm; however, severe focal underdeployment of the midstent was now clearly evident (Fig. 3b). This area was treated with dilatation of a 3.0 mm × 15 mm NC Sprinter to 20 atm but with little angiographic

improvement. A 3 mm × 10 mm OPN NC was delivered and full expansion was obtained within the stent at 28 atm (Fig. 3c), with final angiography confirming uniform stent expansion (Fig. 3d).

Case 4

A 77-year-old female was admitted with an acute coronary syndrome. Angiography showed severe tandem lesions in the proximal and mid LAD (Fig. 4a). A 2.5 mm × 20 mm Ryujin Plus (Terumo Corp, Shibuya-ku, Japan) semicompliant balloon was inflated to

F4

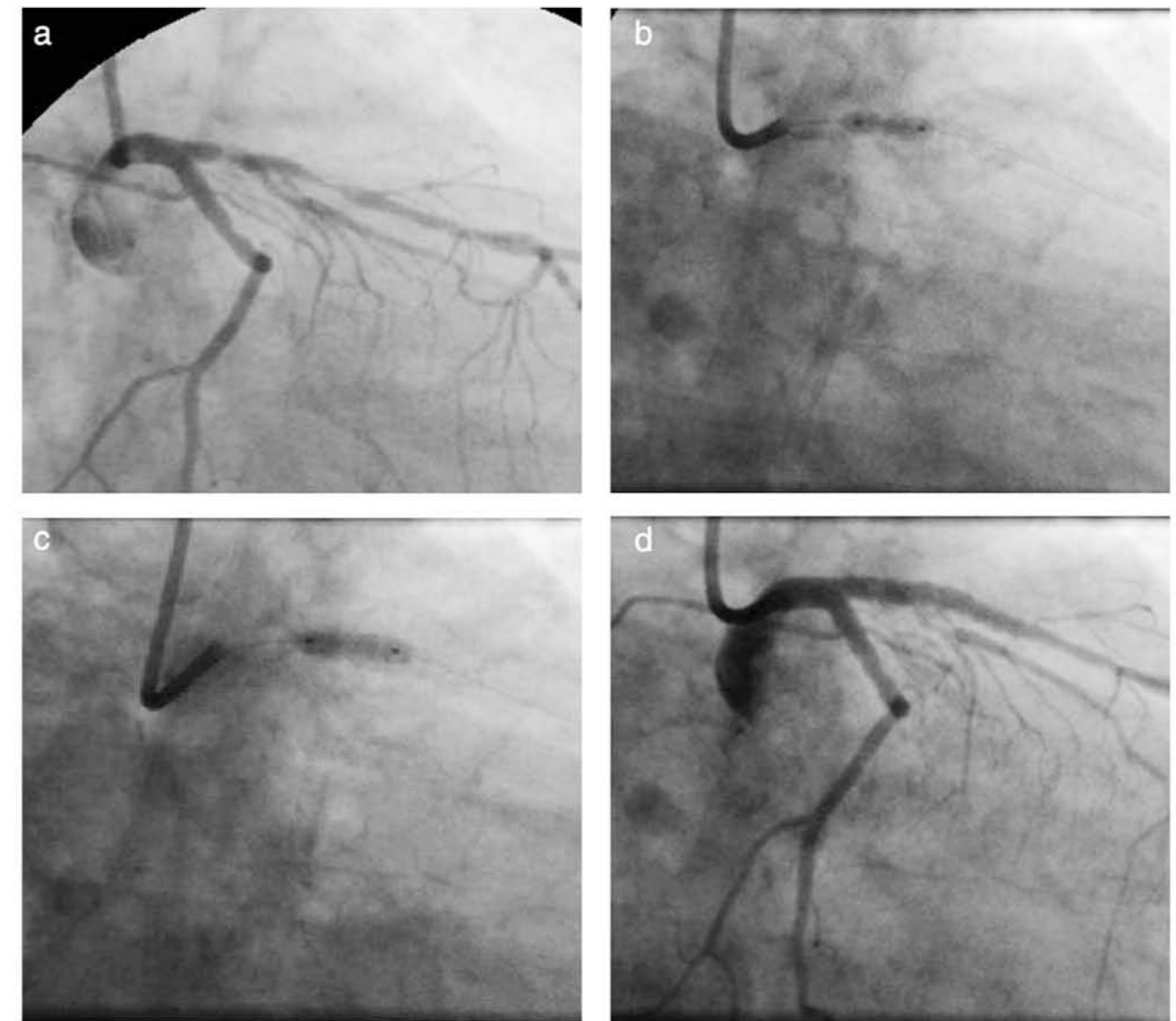


Fig. 4. (a) Diagnostic angiogram (RAO caudal projection) demonstrating severe tandem lesions in the proximal and mid, LAD. (b) A focal area of underexpansion was noted in the 2.75 mm × 23 mm Cypher Select stent deployed at 17 atm, which remained after dilatation with a 3 mm × 9 mm NC Sprinter at 20 atm. (c) The lesion was successfully dilated with a 3 mm × 10 mm OPN NC at 30 atm. (d) Final angiogram showed full, uniform stent expansion.

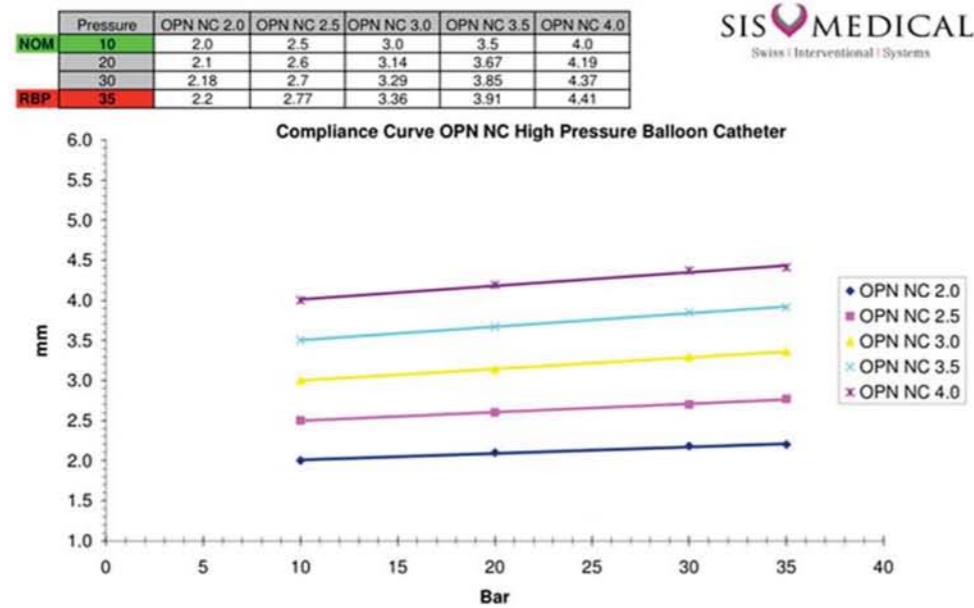


Fig. 5. Compliance curves for the OPN NC. Nominal pressure is 10 atm with rated burst pressure 35 atm. Each balloon is factory tested to 42 atm.

12 atm and although full expansion was noted, in retrospect not all the lesion was treated. A 2.75 mm × 23 mm Cypher Select stent was delivered, with some resistance encountered on its passage, and deployed at 17 atm. A localized area of underexpansion was noticed on the postdeployment angiogram. This lesion remained resistant to high pressure dilatation with a 3 mm × 9 mm NC Sprinter at 20atm (Fig. 4b) but yielded to a 3 mm × 10 mm OPN NC balloon at 30 atm (Fig. 4c). The final angiogram showed full stent expansion (Fig. 4d).

In none of the cases described did use of the OPN NC result in apparent dissection or perforation. All four patients were discharged uneventfully without biomarker evidence of periprocedural infarction. Since introduction in our laboratory, the OPN NC has been used in a total of seven patients in whom resistant lesions were encountered either pre or post stent implantation. Successful lesion dilatation was observed with its use in all cases. We have not yet encountered failure of catheter delivery nor coronary perforation despite use of high inflation pressures.

DISCUSSION

Fibro-calcific plaques reduce vessel distensibility and impair full, uniform balloon dilatation and subsequent stent expansion [10]. Use of noncompliant balloons to achieve full dilatation in resistant lesions is a reasonable first-step. However, focal points of resistance

within a lesion result in nonuniform balloon expansion and characteristic “dog boning” with overexpansion in the more compliant segments, as demonstrated in case 1. It is this nonuniform expansion that may cause vessel dissection and rupture acutely as well as restenosis due to deep-wall injury in the months following.

Cutting Balloons, designed to score the vessel longitudinally rather than causing uncontrolled plaque disruption, have been used successfully in the treatment of undilatable lesions [4]. The rigidity of the blades, however, can limit their ability to reach the target lesion. In addition, blade entrapment [8] and perforation [9] have been reported with their use. The AngioSculpt, a semicompliant balloon surrounded with nitinol spirals, also uses the “focused-force” method [11]. The increased profile of the AngioSculpt may result in failure of balloon retrieval and entrapment of the nitinol wire within heavily calcified lesions has been reported [7]. Rotational atherectomy ablates luminal calcium, modifying and debulking the plaque and may be considered the “gold standard” in the treatment of undilatable lesions. Specialized equipment and training are required, however, and frequent use is essential to its safe application, such that rotational atherectomy may not be available in all cases. This is the first reported clinical experience with the OPN NC, and its position amongst these other available therapies remains to be determined. In Case 3, the OPN NC was successfully used after rotational atherectomy, indicating that in some cases at least, its role may be complementary.

The risk of any device that uses expansive force in the treatment of resistant or calcified lesions is vessel perforation. The particular properties of the OPN NC that may mitigate vessel trauma are its extremely low compliance and resistance to “dog-boning” due to the double-layer construction.

In the cases described a novel, high-pressure balloon, the OPN NC was used successfully after failure to achieve full lesion expansion with other balloons. The device, available in sizes 2.0 to 4.0 mm, is designed specifically for the treatment of calcified lesions and for postdilatation of underdeployed stents. The OPN NC utilizes a twin-layer balloon technology, which permits the use of very high pressure inflations and ensures uniform expansion over a wide range of pressures. The balloon is highly noncompliant (Fig. 5) with a nominal pressure of 10 atm and rated burst pressure of 35 atm. Each balloon is factory tested to 42 atm. To date, the device is available in 30 countries but as yet clinical studies are lacking. As illustrated in this series, the OPN NC can result in successful expansion of lesions and stents in which other standard non-compliant balloons have failed.

The low-profile nature and absence of additional blades or wires result in a highly deliverable catheter. It is also a cost-effective, simple device that requires no additional equipment or specific training and thus may represent an important addition to the options available for the treatment of resistant coronary lesions.

REFERENCES

1. Odink AE, van der LA, Hofman A, Hunink MG, Breteler MM, Krestin GP, Witteman JC. Risk factors for coronary, aortic arch and carotid calcification; The Rotterdam Study. *J Hum Hypertens* 2009.
2. Cavusoglu E, Kini AS, Marmur JD, Sharma SK. Current status of rotational atherectomy. *Cathet Cardiovasc Interv* 2004;62:485–498.
3. Lindsey JB, Banerjee S, Brilakis ES. Two “buddies” may be better than one: use of two buddy wires to expand an underexpanded left main coronary stent. *J Invasive Cardiol* 2007;19:E355–E358.
4. Karvouni E, Stankovic G, Albiero R, Takagi T, Corvaja N, Vagheti M, Di MC, Colombo A. Cutting balloon angioplasty for treatment of calcified coronary lesions. *Cathet Cardiovasc Interv* 2001;54(4):473–481.
5. Fonseca A, Costa JR Jr, Abizaid A, Feres F, Abizaid AS, Costa R, Staico R, Mattos LA, Sousa AG, Grube E, Sousa JE. Intravascular ultrasound assessment of the novel AngioSculpt scoring balloon catheter for the treatment of complex coronary lesions. *J Invasive Cardiol* 2008;20:21–27.
6. Cohen BM, Weber VJ, Relsman M, Casale A, Dorros G. Coronary perforation complicating rotational ablation: The U.S. multicenter experience. *Cathet Cardiovasc Diagn* 1996; Suppl 3:55–59.
7. Sanchez-Recalde A, Galeote G, Martin-Reyes R, Moreno R. AngioSculpt PTCA balloon entrapment during dilatation of a heavily calcified lesion. *Rev Esp Cardiol* 2008;61:1361–1363.
8. Giugliano GR, Cox N, Popma J. Cutting balloon entrapment during treatment of in-stent restenosis: An unusual complication and its management. *J Invasive Cardiol* 2005;17:168–170.
9. Quan VH, Stone JR, Couper GS, Rogers C. Coronary artery perforation by cutting balloon resulting in dissecting subepicardial hematoma and avulsion of the vasculature. *Cathet Cardiovasc Interv* 2005;64:163–168.
10. Nakamura S, Colombo A, Gaglione A, Almagor Y, Goldberg SL, Maiello L, Finci L, Tobis JM. Intracoronary ultrasound observations during stent implantation. *Circulation* 1994;89:2026–2034.
11. de Ribamar CJ Jr., Mintz GS, Carlier SG, Mehran R, Teirstein P, Sano K, Liu X, Lui J, Na Y, Castellanos C, Biro S, Dani L, Rinker J, Moussa I, Dangas G, Lansky AJ, Kreps EM, Collins M, Stone GW, Moses JW, Leon MB. Nonrandomized comparison of coronary stenting under intravascular ultrasound guidance of direct stenting without predilatation versus conventional predilatation with a semi-compliant balloon versus predilatation with a new scoring balloon. *Am J Cardiol* 2007;100:812–817.

Distributed by

Vascularperspectives

innovations for the interventionalist

Vascular Perspectives Ltd
Parkview House
127 Styal Road
Heald Green
Cheadle
Cheshire
SK8 3TG
UK

E-mail info@vascularperspectives.co.uk

Helix_v3/Dec_09

Manufactured by

SIS  MEDICAL

Tel:
0161 491 0585

Fax:
0161 282 6540

Web:
www.vascularperspectives.com

Email:
info@vpmed.co.uk